

Breast Reconstruction with Perforator Flaps

Jay W. Granzow, M.D.,
M.P.H.

Joshua L. Levine, M.D.

Ernest S. Chiu, M.D.

Maria M. LoTempio, M.D.

Robert J. Allen, M.D.

*New Orleans, La.; Charleston, S.C.;
and Torrance, Calif.*

Background: Perforator flaps represent the latest in the evolution of soft-tissue flaps. They allow the transfer of the patient's own skin and fat in a reliable manner, with minimal donor-site morbidity. The powerful perforator flap concept allows transfer of tissue from numerous, well-described donor sites to almost any distant site with suitable recipient vessels. Large-volume flaps can be supported reliably with perforators from areas such as the abdomen, buttock, or flank and transferred microsurgically for breast reconstruction.

Indications: The ideal tissue for breast reconstruction is fat with or without skin, not implants or muscle. Absolute contraindications specific to perforator flaps in the authors' practice include history of previous liposuction of the donor site, some previous donor-site surgery, or active smoking (within 1 month before surgery).

Technique: Perforator flaps are supplied by blood vessels that arise from named, axial vessels and perforate through or around overlying muscles and septa to vascularize the overlying skin and fat. During flap harvest, these perforators are meticulously dissected free from the surrounding muscle, which is spread in the direction of the muscle fibers and preserved intact. The pedicle is anastomosed to recipient vessels in the chest, and the donor site is closed without the use of mesh.

Conclusion: Perforator flaps allow for safe, reliable tissue transfer from a variety of sites and provide ideal tissue for breast reconstruction, with minimal donor-site morbidity. (*Plast. Reconstr. Surg.* 120: 1, 2007.)

The most common type of breast reconstruction involves the use of saline or silicone gel implants. This technique has the advantages of simplicity and the absence of a donor site. Aesthetic results can be quite good, although in the senior author's experience these patients have consistently reported that the result never feels natural and always feels like an implant under the chest muscle. Approximately 25 percent of the women seen for breast reconstruction in the senior author's practice have undergone previous attempted implant reconstruction.

The transverse rectus abdominis musculocutaneous (TRAM) flap in the early 1980s ushered in the new era of autogenous reconstruction. Every plastic surgeon set out to learn this technique.

From the Section of Plastic Surgery, Louisiana State University Health Sciences Center; Division of Plastic Surgery, Medical University of South Carolina; and Division of Plastic Surgery, Harbor-UCLA Medical Center.

A Master Series article from Plastic Surgery 2004.

Received for publication May 18, 2005; accepted February 15, 2006.

Copyright ©2007 by the American Society of Plastic Surgeons

DOI: 10.1097/01.prs.0000256044.66107.a6

Over time, the magnitude of the donor-site morbidity became more apparent. As plastic surgeons, we are always looking for better ways to do things. The deep inferior epigastric perforator (DIEP) and superficial inferior epigastric artery (SIEA) flaps have certainly decreased donor-site morbidity. However, these techniques have brought new difficulties and problems that must be addressed. First and foremost, these techniques require microsurgical expertise. Bill Shaw once said that the super specialist might perform certain types of free flaps beyond the realm of the occasional microsurgeon. What is the learning curve for perforator flap breast reconstruction? Perhaps 50 to 100 procedures.

The variability of vascular anatomy contributes to the difficulties with these procedures. Judgment as to how many and what size and location of perforators to select affect factors such as length of operation and incidence of fat necrosis. Vascular territory depends on the above factors. It is amazing how little blood supply is actually necessary to adequately perfuse skin and fat. Flap inseting also affects flap circulation.

Perforator flaps have allowed the transfer of the patient's own skin and fat in a reliable manner, with minimal donor-site morbidity, for more

than a decade.¹ They represent the most recent development in the evolution of flaps for breast reconstruction. Flaps that relied on a random pattern blood supply were soon supplanted by pedicled, axial pattern flaps that could reliably transfer greater amounts of tissue. The advent of free tissue transfer allowed an even greater range of possibilities to appropriately match donor and recipient sites.²

In 1989, the quest to further reduce donor-site morbidity and flap bulk was led by Koshima and Soeda.³ They succeeded in transferring skin territory above the rectus abdominis muscle based off a perforator vessel to reconstruct a floor-of-mouth and groin defect. In 1992, breast reconstruction using the same principles was developed by Allen and Treece and Allen and Tucker.^{1,4} Abdominal tissue supplied by perforators to the rectus abdominis muscle was transferred with the deep inferior epigastric perforator flap, buttock tissue overlying the gluteus maximus muscle was transferred with the gluteal artery perforator flap, back tissue overlying the latissimus dorsi muscle was rotated with the thoracodorsal artery perforator flap, and lateral thigh skin and fat overlying the tensor fasciae latae muscle were transferred as the lateral thigh perforator flap as new options for breast reconstruction.

The flow of a noncompressible liquid through a tube is governed by Poiseuille's law according to the following equation:

$$\Phi_V = \frac{\pi r^4 \Delta p^*}{8\eta l}$$

The flow of a volume of liquid, Φ_V , is proportional to the fourth power of the radius of the tube through which it is carried. Thus, a single large perforating vessel that is 2.0 mm in diameter will carry approximately 16 times the blood flow of an otherwise similar vessel that is only 1.0 mm in diameter. Therefore, it is preferable to use a single large perforator than multiple, smaller perforators when choosing among vessels to carry a perforator flap.

Relative contraindications for perforator flaps include active nicotine use, obesity with a body mass index greater than 30, and previous liposuction. Immediate perforator breast reconstruction is not recommended in patients scheduled to have radiation therapy after mastectomy.⁹

DIAP FLAP

A good source of this soft tissue for a free flap is the patient's own lower abdomen. Previously, a

TRAM flap could have been used to carry reliably the abdominal skin and fat at the expense of sacrificing the abdominal rectus muscle and fascia. The DIEP flap can carry the same tissue without the sacrifice of the rectus muscle or fascia, thereby minimizing donor-site morbidity and pain and shortening recovery time.⁵⁻⁷

Indications

Most women who have had or will have mastectomies for breast cancer are possible candidates for the DIEP flap. In addition, DIEP flap reconstruction may be used for women requiring additional breast tissue for defects such as a congenital deficiency or lumpectomy defect.⁸ In most patients, DIEP flaps may also be used for head and neck reconstruction or extremity wounds.

Absolute contraindications specific to DIEP flap breast reconstruction in our practice include history of previous abdominoplasty or abdominal liposuction, and active smoking (within 1 month before surgery). Relative contraindications include large transverse or oblique abdominal incisions.

In the case of breast reconstruction, we prefer to have the patient complete any radiation therapy and a delay of 6 months before placement of the free flap. Although the perforator flaps usually tolerate radiation well, a superior long-term result is typically obtained in reconstructions performed after rather than before chest wall irradiation. This spares the flap the damaging effects of radiation and typically results in a better long-term result. It also allows the removal of any thick, stiff irradiated chest wall skin and its replacement with soft and nonirradiated abdominal skin and soft tissue.⁹

Anatomy

Like the free TRAM flap, the DIEP flap is based on the deep inferior epigastric artery and vein. Two rows of perforating arteries and veins penetrate the rectus muscle on each side of the abdomen to provide the blood supply for the overlying skin and fat. The deep inferior epigastric artery is typically between 2 and 3 mm in diameter and the accompanying veins are between 2 and 3.5 mm in size.

Unlike a TRAM flap, the rectus muscle and fascia are spared. Instead, the perforating vessels that supply the overlying skin and fat are carefully followed through the rectus muscle to their origins from the deep inferior epigastric vessels. During the dissection, the rectus muscle itself is spared

and atraumatically separated in the direction of the muscle fibers.

Preoperative Evaluation

The patient is usually seen in the office on the day before surgery for preoperative markings and Doppler studies. The surgical plan again is reviewed with the patient, and remaining questions are also answered at this time.

Standard abdominoplasty markings are made in the sitting or standing position. The side of the abdomen contralateral to the side to be reconstructed is preferred, as this provides for easier inseting at the time of surgery. Flaps are typically marked approximately 12 cm high at the midline and extend approximately 22 to 24 cm laterally from the midline. Then, with the patient in the supine position, a Doppler probe is used to identify the main perforators of the medial and lateral branches of the deep inferior epigastric artery. The superficial inferior epigastric artery and vein are likewise found with the Doppler probe and marked.

Surgical Technique

A two-team approach is used, with simultaneous raising of the flap and preparation of the recipient vessels. The deep inferior epigastric artery usually is between 2.0 and 2.5 mm in diameter, and the accompanying vein usually is between 2.5 and 3.0 mm in diameter. Careful preparation of recipient vessels with similar diameters is preferred.

For breast reconstruction, the internal mammary artery and vein are the recipient vessels of choice and are used in over 90 percent of our cases. The internal mammary vessels are of consistent location and diameter in the majority of the cases. They are not damaged during axillary dissection and typically not negatively affected by radiation therapy. Their central position in the chest makes medial placement of the flap easier on inseting. The vessels are dissected in the second or third intercostal space. A working field with a width of 2 to 3 cm makes the anastomosis to the recipient vessels easier. If the rib space is less than 3 cm in width, the removal of a portion the lower rib is performed. The advantage is to gain length on the recipient vessels, prevent a contour deficiency superior on the chest wall, and prevent injury to the vessels by dissecting more distally. The longer pedicle allows for greater ease of vessel orientation. In approximately 10 percent of cases, we use the internal mammary perforators as re-

ipient vessels. The vein is often 3 mm in diameter. The artery varies from 1 to 2 mm.

The internal mammary recipient vessels are particularly suited to a shorter DIEP pedicle, an SIEA flap, or a gluteal artery perforator (GAP) flap where the flap artery match is better. We use the thoracodorsal vessels when the internal mammary vessels prevent proper flap inseting and geometry, such as in cases of partial breast reconstruction where lateral placement of tissue is required. The thoracodorsal vessels are also used with nipple/areola-sparing mastectomy through an axillary incision.

After the superior and inferior skin incisions are made, the superficial inferior epigastric vessels are identified. If these are found to be of sufficient size and quality, they are followed down to their origin from the common femoral artery and an SIEA flap is performed instead. Often, only the superficial inferior epigastric vein is present of sufficient size, and this is dissected free for several centimeters. This can be used as a backup for the venous drainage of the flap if venous congestion is present after the anastomosis is performed in the chest.

The abdominal skin island is carefully elevated from lateral to medial until the lateral row of perforators is encountered. The lateral perforators are carefully inspected. If a large lateral perforator is found, the flap may be based on this vessel. Additional perforators in the same row may also be dissected and included with the flap for additional perfusion. If no large lateral row perforators are found, the medial row is approached in a similar fashion. If no dominant single perforators are found, two or even three smaller perforators in the same lateral or medial row may be taken to carry the flap. In cases where more than one large perforator is present, the perforator with a more central location to the proposed flap is used. In our experience, approximately 25 percent of flaps are based on one perforator, 50 percent are based on two perforators, and 25 percent are based on three or more perforators. We prefer a flap to be based on a single large perforator. As described above, one large perforator can carry more blood flow than several smaller perforators and is associated with a lower incidence of fat necrosis in the flap.¹⁰ In the case of a unilateral DIEP flap reconstruction, if the medial and lateral row perforators on the initially approached side of the abdomen are found to be less than optimal, the perforators on the opposite side of the abdomen are investigated, as the contralateral side often yields a perforator of better quality.

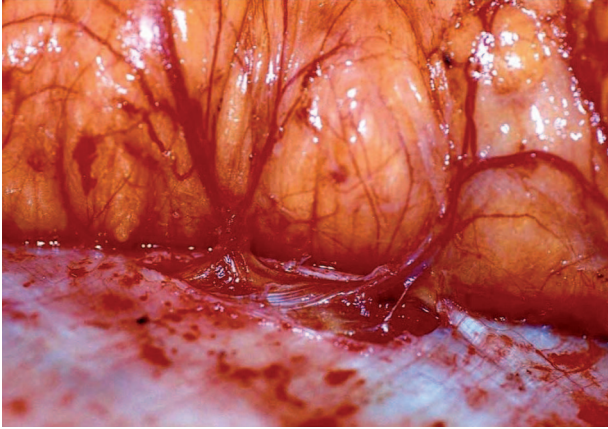


Fig. 1. Perforating vessels of the lateral branch of the deep inferior epigastric artery are visible coursing through the rectus sheath.

Once the appropriate perforators are chosen, the anterior rectus sheath is opened around the perforators and the vessels are carefully dissected down through the rectus muscle to the deep inferior epigastric artery and vein (Fig. 1). The muscle is spread apart in the direction of the fibers, and care is taken to identify and preserve any intercostal nerves innervating the medial aspect of the muscle that might cross the pedicle. Dissection continues until the pedicle is of sufficient length, typically 8 to 10 cm long, and the vessels are a sufficient caliber to match the recipient vessels in the chest. High-power, 4.5 \times or greater loupe magnification and careful microsurgical techniques are essential during this dissection. Pure sensory nerves that innervate the flap skin paddle typically run with the perforators and may also be dissected free for anastomosis into divided recipient sensory nerves in the chest.

When the recipient vessels are prepared, the anterior surfaces of the pedicle vessels at their origin are marked with a surgical marker for vessel orientation in the chest to prevent possible kinking or twisting. The artery and then veins of the pedicle are ligated and the pedicle slid out underneath any crossing intercostal nerves. Sometimes, it is necessary to divide a crossing motor intercostal nerve to release the vascular pedicle. In these cases, the nerve is repaired with two interrupted 8-0 nylon sutures before closure of the abdominal fascia. The flap is then weighed and transferred to the recipient site. Great care is taken to lay the donor pedicle to the recipient vessels without any twists or kinks in the vessels. Although the overall incidence of vascular complications is low, experience has shown that many

cases of venous compromise can be traced to a kinked pedicle. Temporary stay sutures are placed in the flap with the orientation of the 180 degrees with the umbilicus inferiorly. This allows for the thicker part of the flap to lie medially on the chest wall. The operating microscope is brought into position.

Under magnification, the anterior surface of the recipient artery and vein are also labeled with a surgical marker and the larger vein is ligated distally. An anastomotic coupling device typically is used to connect the recipient and flap veins. The coupling device makes the anastomosis easier and faster, and has the additional benefit of stenting the vein open after the vessels are joined. The arterial anastomosis is typically performed with a nylon 9-0 suture with a 100- μ m needle. In the case of a good size match between the flap and recipient arteries, a running suture is used. Otherwise, interrupted sutures are used with a 10-0 suture and a 75- μ m needle. If a size mismatch is observed, identification of a side branch of the artery allows creation of a larger lumen when cut in a plane parallel to the side branch. Other techniques to adjust for the size mismatch are to cut obliquely on the smaller artery or to obtain a vein graft to interpose between the donor and recipient artery. In the literature, reports of telescoping the small recipient artery into the donor artery and also end-to-side anastomosis have been reported.

After completion of the anastomosis, there should be a palpable pulse in the pedicle. We call this the Khoobehi sign after one of our associates, Dr. Kamran Khoobehi, who pointed out its importance. Roger Khoury's prospective study on centers of microsurgical excellence revealed that 20 percent of all microanastomoses have to be redone. Thus, if excellent flow is not present despite adequate blood pressure, one should not hesitate to revise the anastomosis.

Donor-site closure proceeds either during the microanastomosis or concurrent with flap inseting. The abdominal fascia is closed and tied securely with running size 0 absorbable sutures. Mesh or other synthetic materials are not used in abdominal wall closures. The edges of the umbilicus are tacked down to the fascia with 2-0 Vicryl suture (Ethicon, Inc., Somerville, N.J.). The upper abdominal flap is elevated, the patient flexed, and the wound closed in layers over two closed suction drains. Care is taken to approximate Scarpa's fascia with 2-0 interrupted Vicryl sutures. As in an abdominoplasty, the umbilicus is brought out through the abdominal flap and secured in place.

The inseting and closure are performed over a suction drain, and great care is used to monitor the integrity of the pedicle during the inseting of the flap at all times. If a contralateral flap is used, the flap is turned between approximately 90 and 120 degrees such that the medial portion of the abdominal flap becomes the base of the reconstructed breast. The apex of the triangular flap becomes the “tail” of the reconstructed breast. The lateral portion of fat flap may be stabilized with absorbable sutures to the lateral aspect of the pectoralis major muscle to keep the flap from falling out into the axilla and creating additional tension on the anastomosis.

Excess skin is deepithelialized superiorly and inferiorly and the flap inset with a visible skin paddle left in place. A large skin paddle allows easier postoperative monitoring for signs of ve-

nous congestion as well. The external Doppler probe is used to identify the locations on the flap with good arterial and venous signals, and these locations are marked for postoperative monitoring in the intensive care unit and on the floor with the handheld Doppler probe.

An implantable Doppler probe may be used on the vein and/or artery to facilitate postoperative monitoring. This is especially useful in cases where a smaller skin paddle is left or no dominant point can be found on the exposed skin portion of an otherwise healthy flap to allow easy monitoring with the handheld Doppler. Care must be taken with placement of these probes. A Doppler sleeve placed too loosely around the vessel may result in loss of signal despite the presence of good blood flow, whereas a tight sleeve or wire connection may kink or otherwise compromise the vessel's patency (Figs. 2 and 3).

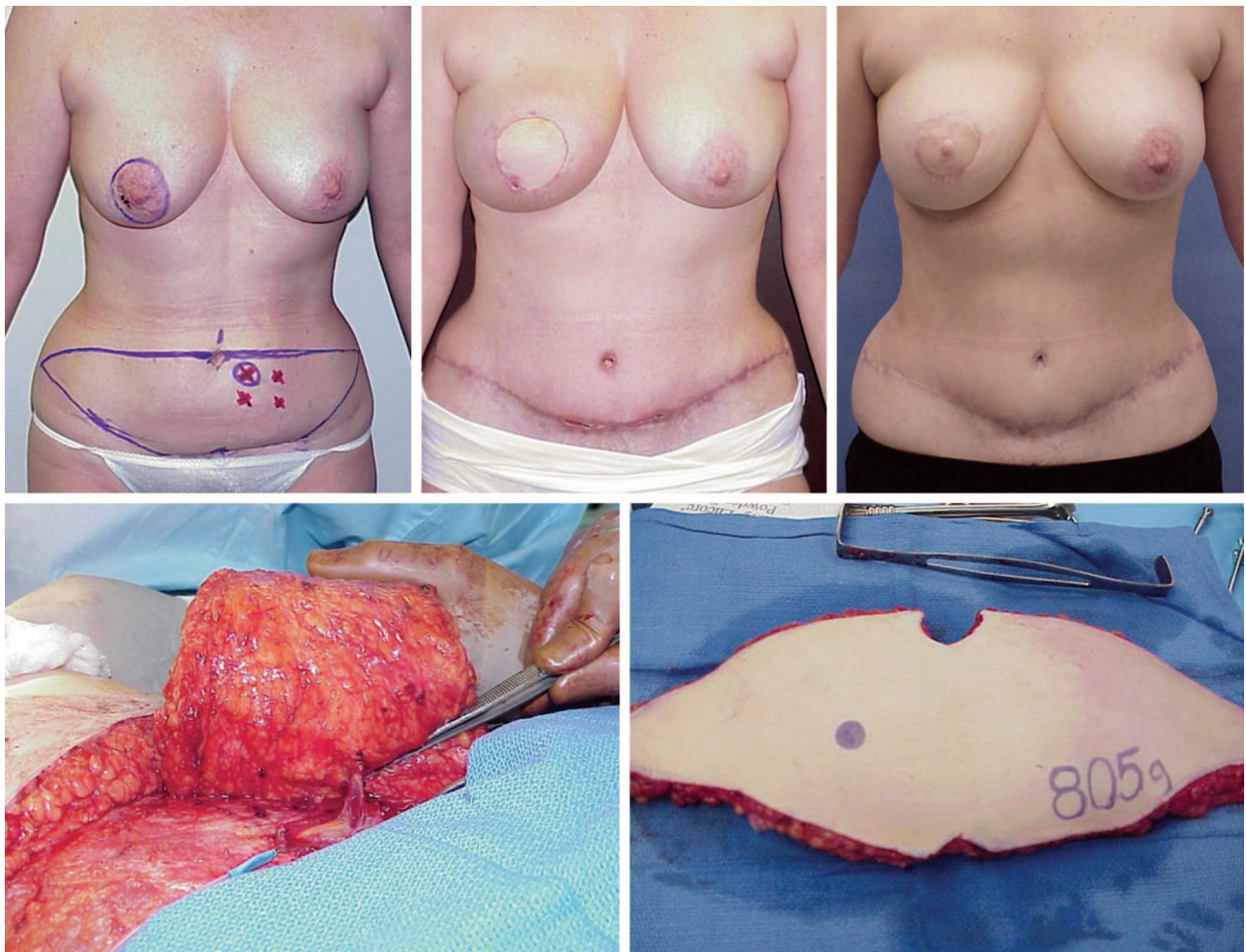


Fig. 2. (Above, left) Preoperative markings for a patient with right breast carcinoma. (Below, left) A DIEP flap raised on the perforator. (Below, right) A DIEP flap after harvest. (Above, center) Photographs of the patient 3 months after initial flap transfer and (above, right) 3 months after nipple construction.

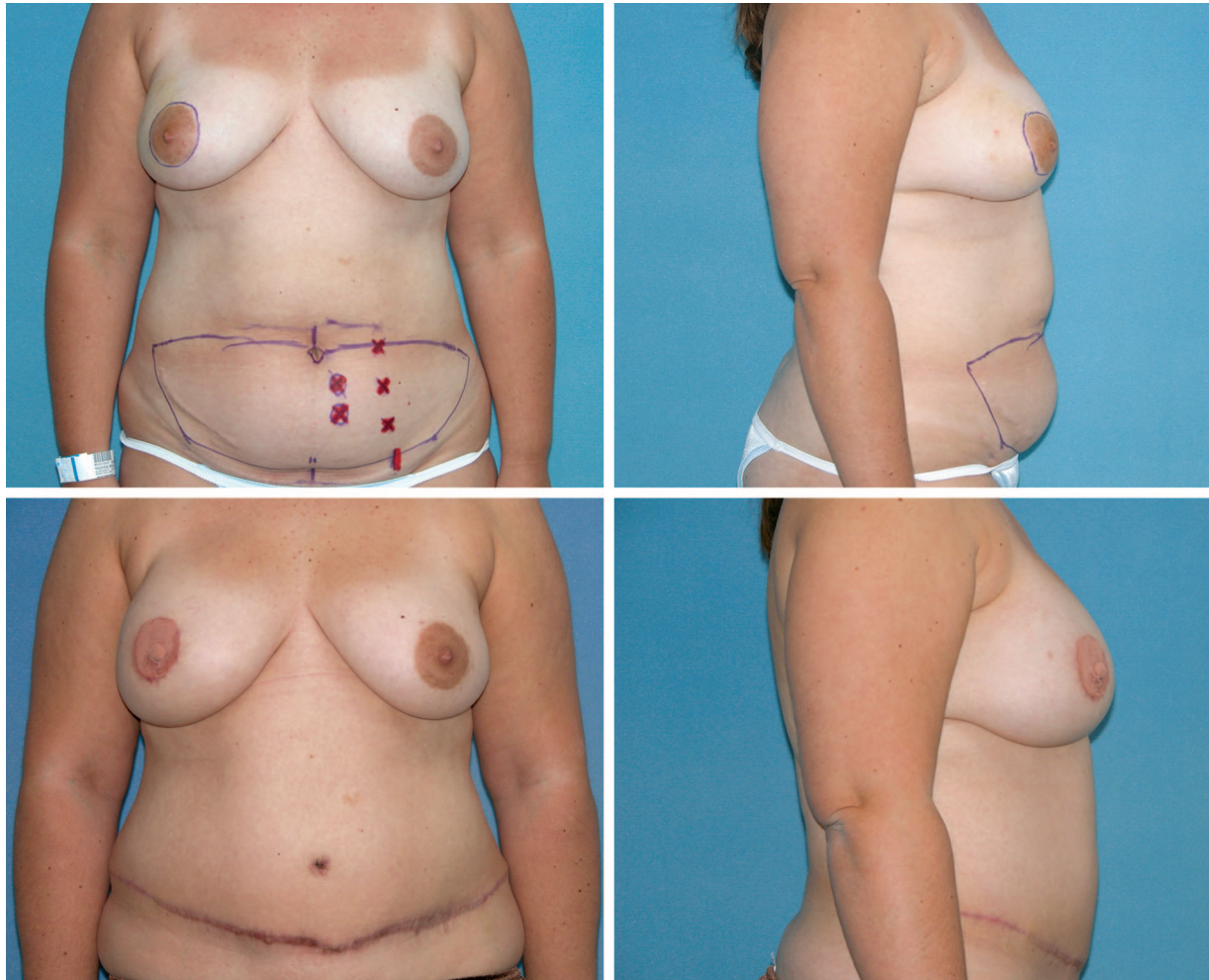


Fig. 3. (Above) Preoperative views of a patient with right breast carcinoma for mastectomy with DIEP flap reconstruction. (Below) Views of the patient approximately 3 months after a second-stage procedure after DIEP flap surgery.

Postoperative Care

Postoperatively, the patient is observed in the surgical intensive care unit overnight and transferred to the floor in the morning of the first postoperative day. As the postoperative pain is significantly less than with TRAM flap reconstruction, oral pain medications are given also beginning on postoperative day 1. Typically, the patient ambulates on postoperative day 1 and is discharged to home on postoperative day 4.

Complications

Complications are infrequent. In our published series of over 750 DIEP flap reconstructions and in subsequent work, 6 percent of patients were returned to the operating room for flap-related problems, but partial flap loss occurred in 2.5 percent and total flap loss occurred in less than 1 percent of all cases. Problems with the vein or

venous anastomosis were almost eight times more likely than problems with the artery or arterial anastomosis. Fat necrosis appeared in 13 percent of flaps. Seroma formation at the abdominal donor site was approximately 5 percent and abdominal hernia occurred in 0.7 percent of cases.¹⁰

SIEA FLAP

The SIEA flap provides the same abdominal skin and fat for reconstruction as the DIEP flap. Of the two flaps, the SIEA causes less donor-site morbidity, as no incision must be made in the abdominal fascia and no vessel dissection is performed through the rectus abdominis muscle. There is minimal to no risk of a new abdominal hernia and even less abdominal pain than with other abdominal flaps.

However, the SIEA flap is limited by variability in its vascular anatomy and skin territory. The superficial inferior epigastric artery and vein are

only inconsistently present in sufficient caliber to reliably support sufficient tissue for a breast reconstruction. The superficial inferior epigastric artery and the superficial circumflex iliac artery enter into the common femoral as a common trunk only 60 percent of the time. Therefore, time and energy may be invested in a dissection that yields only an artery of insignificant caliber at the end of the dissection. A common trunk usually means a better size match with the internal mammary artery.

The amount of skin and fat that may be safely carried by an SIEA flap is limited to zones I and II (the ipsilateral side). Of course, this varies depending on the particular vascular anatomy, which is quite variable. Because the course of the SIEA is lateral to the anterior rectus sheath, one would expect the vascular territory to be different from the DIEP flap. Because the vascular pedicle extends from one side of the flap, inseting at the recipient site may be more difficult as compared with the DIEP flap. The flap often needs to be rotated counterclockwise to avoid kinking and redundancy of the pedicle.

Indications

The indications for the SIEA flap are the same as those for the DIEP flap.

Anatomy

The SIEA flap is based on the superficial inferior epigastric artery and vein. The anatomy of these vessels is quite variable. In two series, the superficial inferior epigastric artery was present in 65 to 72 percent of cases.^{2,11} In the series by Allen et al., the average diameter at the point the artery crossed the inguinal ligament was 1.66 mm. The artery was present in 58 percent of both groins and absent in 9 percent of both groins.¹² The veins can also be variable. The venae comitantes may be adequate to drain the flap, or the separate, more medial superficial inferior epigastric vein may be necessary to drain the flap.

Surgical Technique

The markings, preoperative preparation, and operating room setup are the same for the SIEA flap as with the DIEP flap. During flap harvest, the superficial inferior epigastric vessels are approached first. If these vessels are found to have sufficient caliber (approximately 1.0 to 1.5 mm) at the level of the inferior flap incision, they are followed down to their origin from the common femoral artery and saphenous vein.

Preparation of the recipient site is the same as described above for the DIEP flap. However, as the artery of the SIEA flap pedicle is typically smaller than that of a DIEP flap, the procurement of smaller recipient vessels is preferable. If obtainable, the internal mammary artery perforators have a better size match than the internal mammary artery itself. The thoracodorsal vessels offer an advantage also, as they provide a greater range of arterial sizes to better match the SIEA.

The microsurgical anastomosis, flap inseting, and abdominal closure proceed as described above. Abdominal fascial closure is unnecessary (Fig. 4). An SIEA flap may be harder to inset because of the location of the pedicle, which exits at the edge of the flap. Also, a pedicle that is too long may kink when using the internal mammary vein unless the flap is rotated.

Postoperative Care

The postoperative care is the same as with the DIEP flap, and patients typically go home on the fourth postoperative day.

Complications

Complications for the SIEA flap are similar to those for the DIEP flap. In a review of over 200 SIEA flap breast reconstructions, rates of return to the operating room and arterial and venous insufficiency are similar to those found with DIEP flap reconstructions. Only one flap loss occurred in our series. The rate of abdominal seroma formation was slightly higher; approximately 9 percent versus 3.5 percent for the DIEP flap, possibly because of the increased dissection causing disruption around the inguinal lymphatics as required by this procedure.¹³ It is necessary to continue drain placement until the drainage is less than 40 cc in a 24-hour period.

GAP FLAPS

The GAP flap for breast reconstruction was first introduced by our group in 1993.⁴ It is a good choice for breast reconstruction when the abdomen is not. In patients we see for breast reconstruction, the buttock is the donor site in 22 percent and the abdomen in 78 percent. As with the DIEP and SIEA flaps, donor-site morbidity is minimal and no sacrifice of muscle is required. Various locations, orientations, and dimensions of the skin island have been attempted over the years. Each has advantages and disadvantages. Initially, we used an oblique ellipse totally over the muscle oriented in the direction of the muscle. This gives

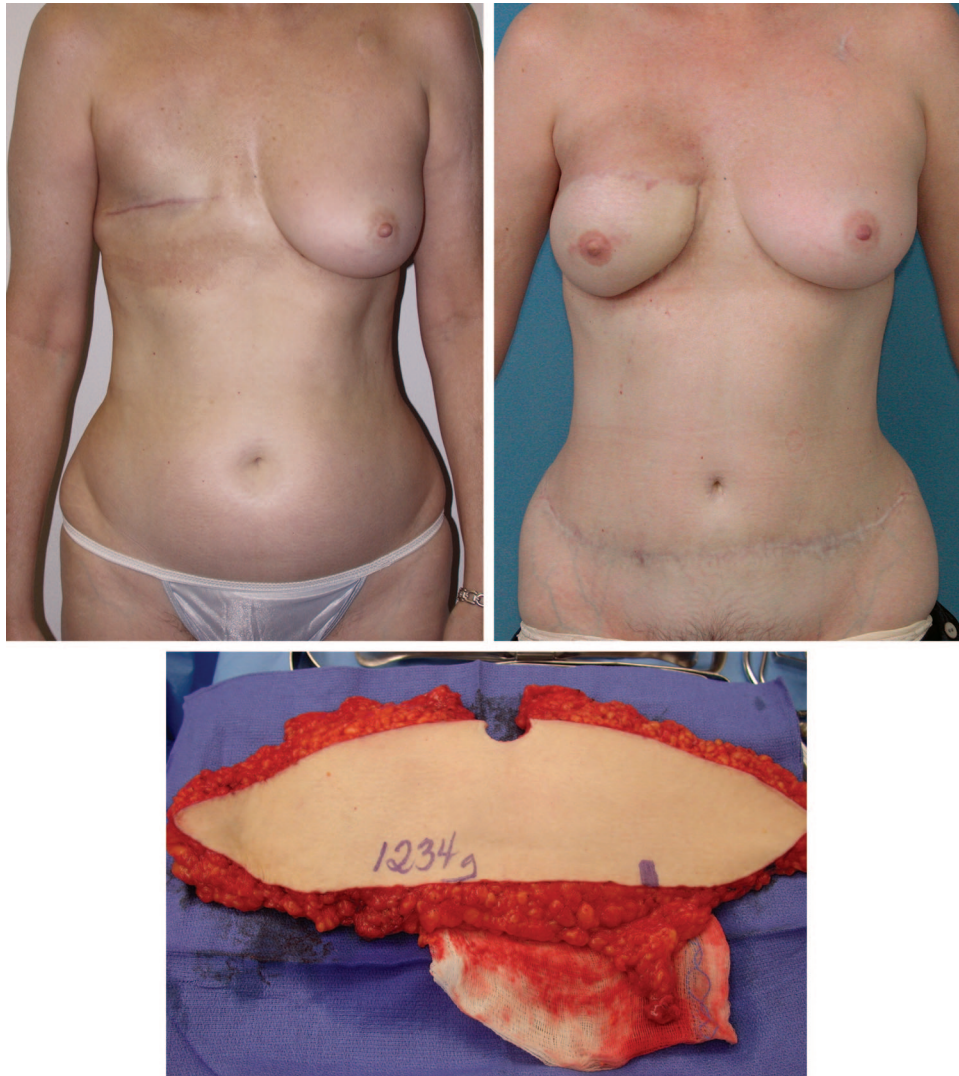


Fig. 4. (Above, left) Preoperative markings. (Below) The SIEA flap after harvest. (Above, right) Photograph of the patient approximately 3 months following the second stage after SIEA reconstruction.

the greatest chance of finding an adequate perforator under the flap. With better appreciation of the vascular anatomy and confidence in the handheld Doppler, there is more freedom in designing the skin island. An oblique ellipse extending superior from medial to lateral has the advantage of concealing the scar in swimwear and undergarments. By beveling superiorly, a nicely shaped flap with less contour deformity can be obtained. We have used both the superior GAP (SGAP) and the inferior GAP (IGAP) flap since 1993. In 2004, we began designing the IGAP flap so that the scar would be in the natural inferior crease.¹⁴ By harvesting tissue from the lowest part of the buttock, the shape of the rounded upper buttock was preserved. The pedicle length was also longer than that of the SGAP flap, making the anasto-

mosis easier and negating the need to remove rib cartilage because less length was required on the recipient vessels. However, sitting directly on the healing incision causes more pain than the SGAP flap, and the rate of dehiscence increases. This is particularly true in bilateral simultaneous reconstructions, where the patient cannot shift weight bearing to the side that was not operated on. The sciatic nerve has never been a problem in my experience of 329 GAP flaps (approximately 100 IGAP flaps). The ideal candidate is someone with a large buttock (pear shape) and a B size breast. In the right candidate, the in-the-crease IGAP flap can provide for excellent breast reconstruction, with a hardly noticeable donor site. After initial overenthusiasm with the in-the-crease IGAP flap, we are now back to the

SGAP flap in slightly more than 50 percent of patients. The women do their research and come with their opinions about which GAP flap they prefer.

Indications

The buttock has a high fat-to-skin ratio, whereas the abdomen has a high skin-to-fat ratio. Patients who require mostly fat and little skin may be candidates for GAP flaps. Patients in whom the abdomen cannot be used as a donor site or who have more tissue in the buttock area than in the abdomen are the best candidates. In our experience using GAP flaps for breast reconstruction, the average final inset weights of our GAP flaps were slightly greater than weights of the mastectomy specimens removed.^{15,16}

Absolute contraindications specific to GAP flap breast reconstruction in our practice are similar to those mentioned above, and include history of previous liposuction at the donor site or active smoking (within 1 month before surgery). Liposuction of the central buttock is rare, but liposuction of the saddlebag area can affect the IGAP flap and liposuction of the hips can affect the SGAP flap.

Anatomy

The SGAP and IGAP flaps are based on perforators from the superior and inferior gluteal arteries and veins, respectively. The superior gluteal artery arises from the internal iliac artery and exits the pelvis superior to the piriformis muscle. It enters the gluteus maximus muscle approximately one-third of the distance along the line between the posterior superior iliac spine and the greater trochanter.

The inferior gluteal artery is a terminal branch of the internal iliac artery and leaves the pelvis through the greater sciatic foramen inferior to the piriformis muscle. The artery is accompanied by the greater sciatic nerve, the internal pudendal vessels, and the posterior femoral cutaneous nerve. The course of the inferior gluteal vessels is more oblique through the gluteus maximus muscle substance than the course of the superior gluteal vessels. Therefore, IGAP pedicle is typically longer than that of the SGAP. Between two and four perforating vessels from the inferior gluteal artery will be located in the lower half of each gluteal muscle.

Perforating vessels that nourish the medial portions of the buttock have relatively short intramuscular lengths, whereas perforators that

nourish the lateral portions of the overlying skin paddle must travel through the muscle in a more oblique manner. Therefore, pedicles based on perforators from the lateral aspects of the skin paddle tend to be longer than those based on more medial perforators.

Surgical Technique

The patient usually is seen in the office 1 day before surgery. The surgical plan again is reviewed with the patient, and any remaining questions are answered.

In SGAP flap marking for unilateral reconstruction, the patient is placed in lateral decubitus position and the Doppler probe used to find perforating vessels from the superior gluteal artery. These are usually found approximately one-third of the distance on a line from the posterior superior iliac crest to the greater trochanter. Additional perforators may be found slightly more lateral from above. The skin paddle is marked in an oblique pattern from inferior medial to superolateral to include these perforators (Fig. 5, *above, left, and center, left*). The lateral third of the flap is not over the gluteus muscle. In bilateral simultaneous reconstructions, the flaps are marked with the patient prone because this is the position in which the flaps will be harvested simultaneously.

For the IGAP flap, the gluteal fold is noted with the patient in the standing position. The inferior limit of the flap is marked 1 cm inferior and parallel to the gluteal fold. The patient is then placed in the lateral position and the Doppler probe is used to find perforating vessels from the inferior gluteal artery. An ellipse is drawn for the skin paddle to include these perforators, which roughly parallels the gluteal fold with dimensions of approximately 8 × 18 cm. As with the SGAP flap, bilateral cases are marked with the patient in the prone position.

For unilateral procedures, the patient is placed in the lateral decubitus position and a two-team approach is used. The recipient vessels are prepared as described above while the GAP flap is harvested. For breast reconstruction, the internal mammary vessels are preferred, as anastomosis to these vessels allows easier medialization of the flap when it is inset. This is especially important for the SGAP flap, which typically has a shorter pedicle than the IGAP flap. However, the IGAP flap often has a long enough pedicle to reach the thoracodorsal vessels.

The skin incisions are made and Bovie electrocautery is used to divide the flap down to the

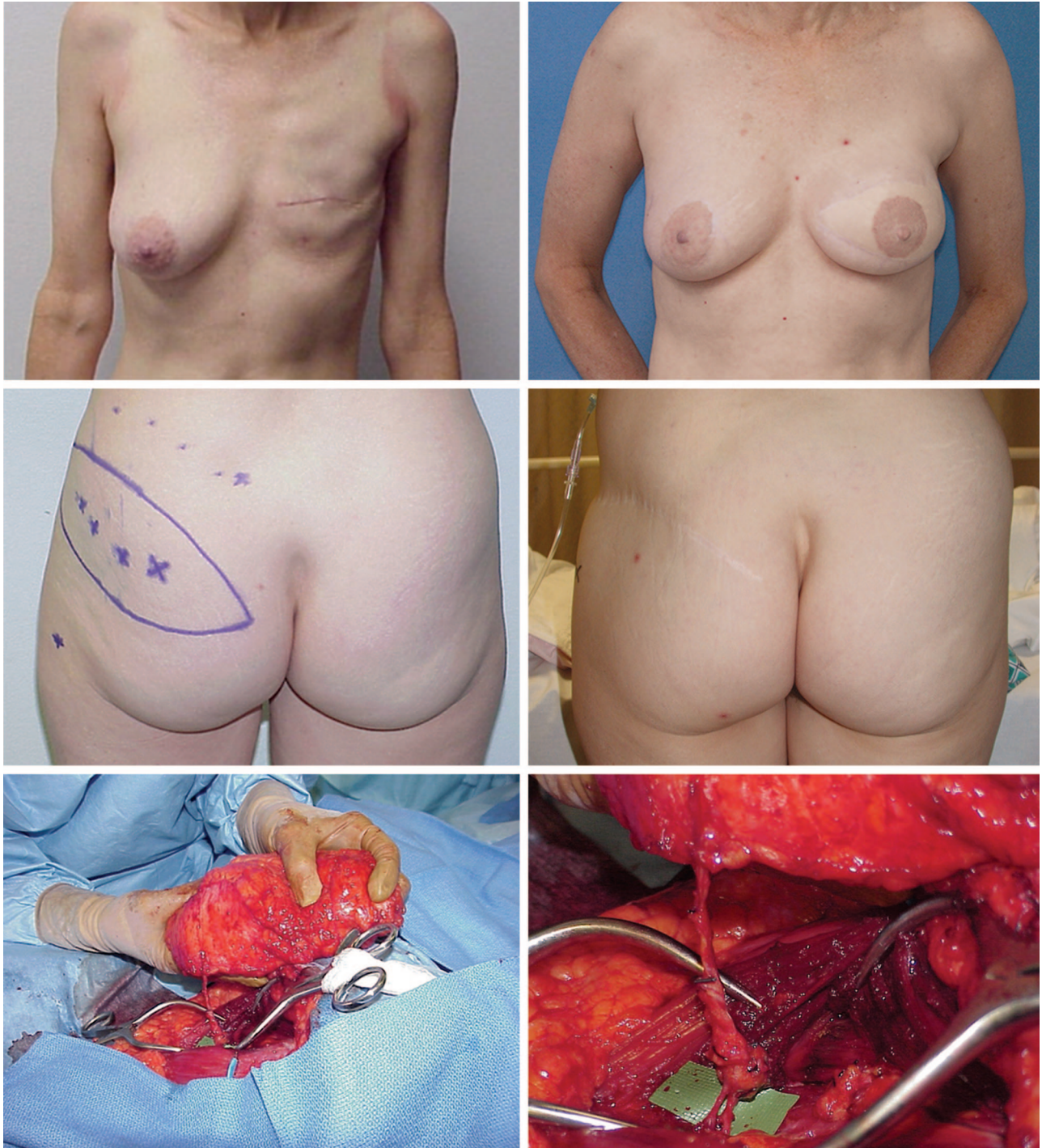


Fig. 5. (Above, left and center, left) Preoperative marking of patient to undergo left breast reconstruction with the SGAP flap. (Below, left and right) Intraoperative views of the SGAP flap and pedicle. (Above, right, and center, right) Views of the patient 3 months following second-stage surgery and nipple creation.

muscle of the gluteus maximus. Significant beveling is used as needed, particularly in the superior direction to harvest enough tissue for a good breast reconstruction. The flap is elevated from the muscle in the subfascial plane and the perforators

approached beginning from lateral to medial. It is preferred to use a single large perforator, if it is present, but several perforators that lay in the same plane and the direction of the gluteus maximus muscle fibers can be taken together as

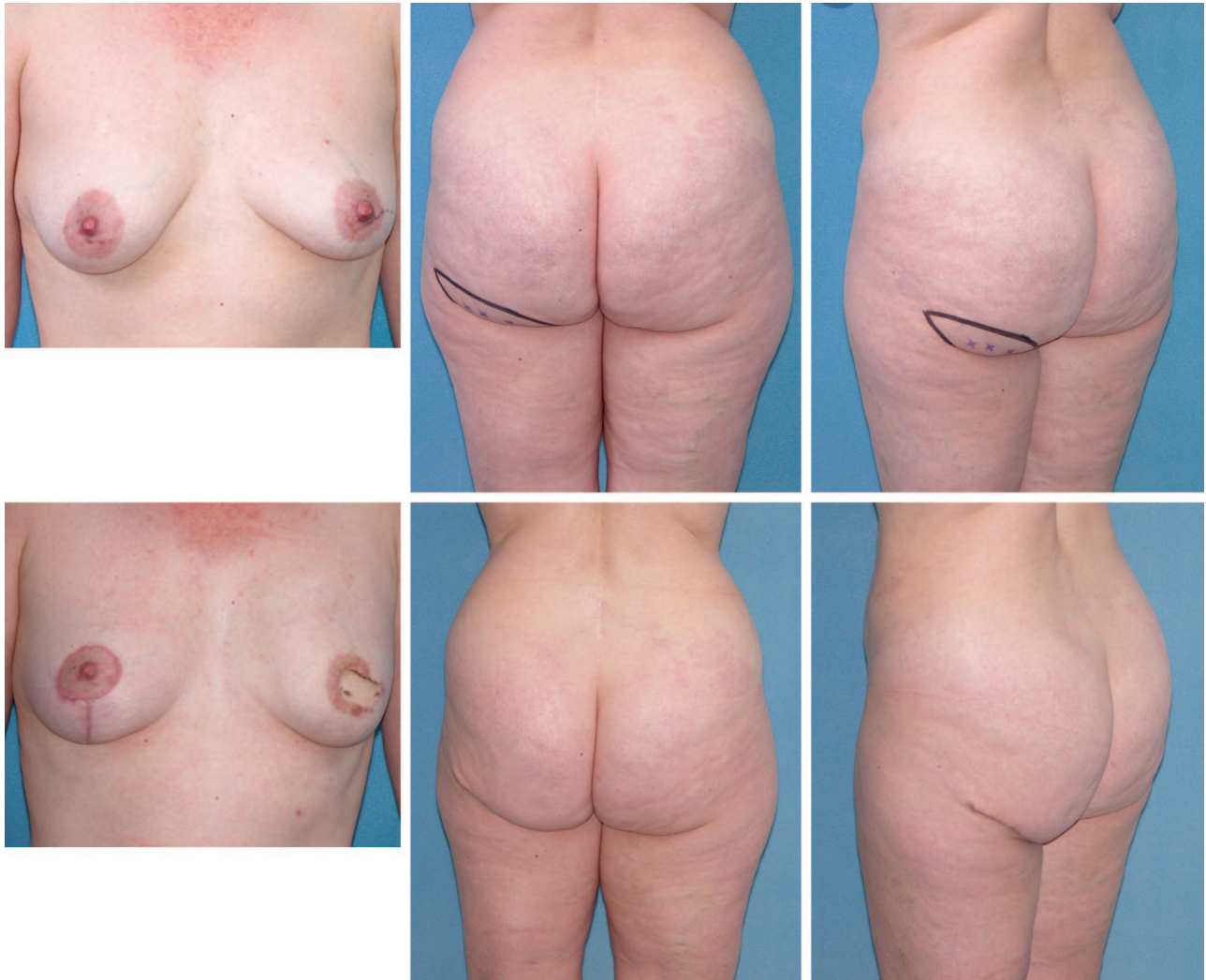


Fig. 6. (Above) Preoperative markings of patient to undergo left breast reconstruction with a left IGAP flap. (Below) Views of the patient 3 months after reconstruction of the left breast with the IGAP flap.

well. Subfascial elevation is also performed from medial to lateral to ensure that a large perforator is found. The muscle is then spread in the direction of the muscle fibers and the perforating vessels are meticulously dissected free. The dissection continues until both the artery and the vein are of sufficient size to be anastomosed to the recipient vessels in the chest. The artery usually is the limiting factor in this dissection. The arterial perforator is visualized and preserved as it enters the main superior or inferior gluteal artery. The preferable artery and vein diameter for anastomosis is 2.0 to 2.5 mm and 3.0 to 4.5 mm, respectively. When using internal mammary vein perforators as recipients, a shorter pedicle and smaller artery will suffice.

Harvesting the in-the-crease IGAP flap allows more beveling superiorly and inferiorly because

soft-tissue deficiency in the crease is normal. Laterally, thicker fat from trochanteric area can be taken, increasing flap volume and decreasing a saddlebag deformity. When harvesting the IGAP flap, care must be taken to preserve the lighter colored medial fat pad that overlies the ischium. Preservation of the fat pad will prevent possible donor-site discomfort when the patient is sitting.

When the recipient vessels are ready, the gluteal artery and vein are divided and the flap is harvested and weighed. The skin and fat overlying the gluteus maximus muscle are elevated superiorly and inferiorly to allow layered approximation of the fat of the donor site to prevent a contour deformity and give a buttock lift. The donor site is closed in layers over a suction drain with absorbable suture. Adding a permanent removable skin suture increases the strength of the closure

(Fig. 5, below, left and right, above, right, and center, right).

The anastomosis is performed to the recipient vessels under the operating microscope. The flap is inset over a suction drain into the defect with care taken not to twist or kink the pedicle. To create a spherical flap, the ends of the ellipse are excised. The flap may be inset horizontally, vertically, or obliquely, depending on the situation (Fig. 6).

Postoperative Care

The postoperative care is the same as with the DIEP flap, and patients typically go home on the fourth postoperative day. The drain at the donor site must usually be left in place for several days longer than with an abdominal donor site.

Complications

In a review of 170 GAP flaps performed by our unit for breast reconstruction, the incidence of complications was low. The overall take-back rate was approximately 8 percent, with a 6 percent rate of vascular complications. The total flap failure rate was approximately 2 percent. Donor-site seroma occurred in 2 percent of patients, and approximately 4 percent of patients required revision of the donor site.^{15,16}

SUMMARY

Perforator flaps have raised the standard in breast reconstruction. By replacing like with like, we can achieve permanent natural results, with minimal donor-site deformities. Being able to choose from many donor-site options makes virtually all patients candidates for this method of autogenous reconstruction. To make this option more available and desirable, there is plenty of room for improvement. The length of the procedure needs to be decreased, scars need to be improved, and complications need to be decreased. With improvements in technology and technique, these goals can be realized.

Robert Allen, M.D.
Suite 180
1300 Hospital Drive
Mount Pleasant, S.C. 29464

DISCLOSURE

None of the authors has a financial interest in any medical device or product mentioned in this article.

REFERENCES

- Allen, R. J., and Treece, P. Deep inferior epigastric perforator flap for breast reconstruction. *Ann. Plast. Surg.* 32: 32, 1994.
- Taylor, G. I., and Daniel, R. K. The anatomy of several free flap donor sites. *Plast. Reconstr. Surg.* 56: 243, 1975.
- Koshima, I., and Soeda, S. Inferior epigastric artery skin flaps without rectus abdominis muscle. *Br. J. Plast. Surg.* 42: 645, 1989.
- Allen, R., and Tucker, C., Jr. Superior gluteal artery perforator free flap for breast reconstruction. *Plast. Reconstr. Surg.* 95: 1207, 1995.
- Futter, C. M., Webster, M. H., Hagen, S., and Mitchell, S. L. A retrospective comparison of abdominus muscle strength following breast reconstruction with a free TRAM or DIEP flap. *Br. J. Plast. Surg.* 53: 578, 2000.
- Kaplan, J., and Allen, R. Cost-based comparison between perforator flaps and TRAM flaps for breast reconstruction. *Plast. Reconstr. Surg.* 105: 943, 2000.
- Kroll, S., Sharma, S., Koutz, C., et al. Postoperative morphine requirements of free TRAM and DIEP flaps. *Plast. Reconstr. Surg.* 107: 338, 2001.
- Allen, R., and Heitland, A. Autogenous augmentation mammaplasty with microsurgical tissue transfer. *Plast. Reconstr. Surg.* 112: 91, 2003.
- Rogers, N., and Allen, R. Radiation effects on breast reconstruction with the deep inferior epigastric perforator flap. *Plast. Reconstr. Surg.* 109: 1919, 2002.
- Gill, P., Hunt, J., Guerra, A., et al. A 10-year retrospective review of 758 DIEP flaps for breast reconstruction. *Plast. Reconstr. Surg.* 113: 1153, 2004.
- Reardon, C., O'Ceallaigh, S., and O'Sullivan, S. An anatomical study of the superficial inferior epigastric vessels in humans. *Br. J. Plast. Surg.* 57: 515, 2004.
- Allen, R. J. The superficial inferior epigastric artery free flap: An anatomic and clinical study for use in reconstruction of the breast. In *Proceedings of the Annual Meeting of the Southeastern Society of Plastic and Reconstructive Surgeons*, Kiawah, S.C., June 3–7, 1990.
- Granzow, J. W., Levine, J. L., Chiu, E. S., et al. Breast reconstruction with the SIEA flap revisited: An 8-year review of 203 cases (unpublished data).
- Babineaux, K. L., Granzow, J. W., Bardin, E., et al. Microvascular breast reconstruction using buttock tissue: The preferred scar location and shape. *Plast. Reconstr. Surg.* 116 (Suppl.): 174, 2005.
- Allen, R. J., Levine, J. L., and Granzow, J. W. The in-thecrease inferior gluteal artery perforator flap for breast reconstruction. *Plast. Reconstr. Surg.* 118: 333, 2006.
- Guerra, A., Metzinger, S., Bidros, R., Gill, P. S., Dupin, C. L., and Allen, R. J. Breast reconstruction with gluteal artery perforator (GAP) flaps: A critical analysis of 142 cases. *Ann. Plast. Surg.* 52: 118, 2004.